




Movement disorders and neuropathies: overlaps and mimics in clinical practice

Francesco Gentile^{1,2} · Alessandro Bertini^{1,2} · Alberto Priori^{1,2} · Tommaso Bocci^{1,2} 

Received: 13 May 2022 / Accepted: 16 May 2022 / Published online: 3 June 2022
© The Author(s), under exclusive licence to Springer-Verlag GmbH Germany 2022

Abstract

Movement disorders as well as peripheral neuropathies are extremely frequent in the general population; therefore, it is not uncommon to encounter patients with both these conditions. Often, the coexistence is coincidental, due to the high incidence of common causes of peripheral neuropathy, such as diabetes and other age-related disorders, as well as of Parkinson disease (PD), which has a typical late onset. Nonetheless, there is broad evidence that PD patients may commonly develop a sensory and/or autonomic polyneuropathy, triggered by intrinsic and/or extrinsic mechanisms. Similarly, some peripheral neuropathies may develop some movement disorders in the long run, such as tremor, and rarely dystonia and myoclonus, suggesting that central mechanisms may ensue in the pathogenesis of these diseases. Although rare, several acquired or hereditary causes may be responsible for the combination of movement and peripheral nerve disorders as a unique entity, some of which are potentially treatable, including paraneoplastic, autoimmune and nutritional aetiologies. Finally, genetic causes should be pursued in case of positive family history, young onset or multisystemic involvement, and examined for neuroacanthocytosis, spinocerebellar ataxias, mitochondrial disorders and less common causes of adult-onset cerebellar ataxias and spastic paraparesis. Deep phenotyping in terms of neurological and general examination, as well as laboratory tests, neuroimaging, neurophysiology, and next-generation genetic analysis, may guide the clinician toward the correct diagnosis and management.

Keywords Movement disorders · Peripheral neuropathy · Parkinsonisms · a-Synuclein · Inflammatory · Paraneoplastic · Genetics

Introduction

The term “movement disorders” encompasses a wide group of neurological conditions characterized by abnormal increased movements (hyperkinesias) or reduced and slowed movements (hypokinesias). The association between movement disorders and peripheral neuropathy (PN) is poorly highlighted in literature. Since movement disorders and neuropathy share the same

pathophysiological mechanism in various neurological syndromes, they may coexist or be a continuum of the same clinical spectrum. Furthermore, both may add to comorbidity and disability independently of the primary neurological manifestation, contributing to pain, reduced motor performance, falls and disability. Therefore, it is important to consider that neuropathy associated with a movement disorder may be not only a useful telltale in the diagnosis of complex syndromes but also a predictor of frailty. Furthermore, an increased awareness of overlapping pathologies presenting to movement disorders or neuromuscular clinics should be warranted, since atypical presentations may overcome classic boundaries between the two fields [1], as well as there may be occasions in which some neurological signs may be misinterpreted or overlooked due to the risk of restricted view in the ultra-specialty setting [2]. Finally, advancing technologies allowed the phenotypic spectrum expansion of numerous hereditary neurological disorders and the availability of next-generation sequencing (NGS) techniques is rapidly

✉ Tommaso Bocci
tommaso.bocci@unimi.it;
tommaso.bocci@asst-santipaolocarlo.it

¹ Clinical Neurology Unit, “Azienda Socio-Sanitaria Territoriale Santi Paolo E Carlo” and Department of Health Sciences, University of Milan, Via Antonio di Rudinì 8, 20142 Milan, Italy

² “Aldo Ravelli” Center for Neurotechnology and Experimental Brain Therapeutics, Department of Health Sciences, University of Milan, Via Antonio di Rudinì 8, 20142 Milan, Italy

changing the way we approach genetic disorders. In this review, we aim to provide a guide for the differential diagnoses and potential causes in patients with concomitant neuropathy and movement disorders, offering a dual clinical approach according to the predominant neurological feature (Fig. 1). Pathogenic mechanisms will be further discussed to serve as cues of potential genotype–phenotype correlations, which will steer diagnostic workup and subsequent therapeutic management (Tables 1, 2).

Methods

Research strategies included screening literature on PubMed and Google Scholar databases updated until 30th April 2022. The search keywords were (“neuropathy” or “polyneuropathy” or “coronavirus”) AND (“movement disorder” or “tremor” or “chorea” or “parkinsonism” or “myoclonus” or “dystonia”). Two authors (F.G. and A.B.) screened records of search outputs for pertinence to the topic and English language only. After data review and summary, we drew a simplified diagnostic algorithm for the approach of patients with concomitant peripheral neuropathy and movement disorders according to the predominant clinical presentation (Fig. 1).

Movement disorders with neuropathy

Sporadic MDS with neuropathies

Parkinson disease

PD is the second most common neurodegenerative disorder in the elderly population after Alzheimer’s disease and typically characterized by asymmetric bradykinesia, rigidity and rest tremor. The relationship between PD and PN has gained attention in recent years. PN is relatively frequent in the general PD population, with an estimated prevalence of 16% [3], presenting as an axonal, predominantly sensory, neuropathy with neuropathic pain, tingling, numbness and sometimes ataxia. PN may add to PD comorbidity by affecting balance and gait, increasing risk of falls and cumulative disability [4, 5]. A multicentre case–control study provided evidence that the duration of levodopa exposure and the daily levodopa dose, instead of disease severity or duration, were strongly associated with the risk of developing medium–large fibre neuropathy in PD patients [6]. Prolonged levodopa exposure was strongly linked to reduced serum vitamin B12 levels and increased homocysteine (Hcy) and methylmalonic acid (MMA) levels [6–8], possibly due to depletion of methyl groups needed for levodopa metabolism and cobalamin malabsorption, which may underlie PN

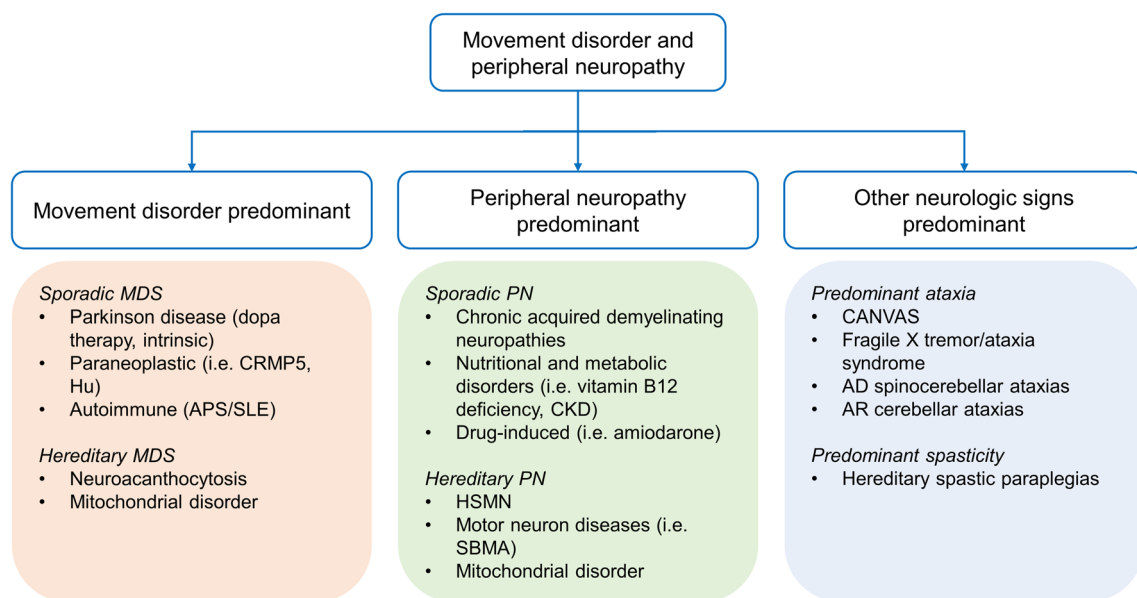


Fig. 1 Clinical approach to patients with movement disorder and peripheral neuropathy. It may be useful to divide the list of differential diagnosis according to the predominant neurological feature, whether it be movement disorder, peripheral neuropathy or other neurological signs. For sake of simplicity, we further categorized disorders on acquired or hereditary aetiologies. *AD*, autosomal dominant;

APS/SLE, antiphospholipid syndrome/systemic lupus erythematosus; *AR*, autosomal recessive; *CANVAS*, cerebellar ataxia, neuropathy and vestibular areflexia syndrome; *CKD*, chronic kidney disease; *HSMN*, hereditary sensory and motor neuropathy; *MDS*, movement disorder; *PN*, peripheral neuropathy; *SBMA*, spinal and bulbar muscular atrophy

Table 1 Acquired and hereditary MDS with peripheral neuropathy

Acquired MDS plus PN syndromes	Disease markers	Onset	Movement disorder	Neuropathy associated	Peculiar features	Imaging-laboratory findings
<i>Parkinson disease</i>		Late onset	Bradykinesia, rigidity, tremor, postural instability	Axonal, large-fibre, mainly sensory (16%) Small fibres (50%) Autonomic (60–70%)	Parkinsonism, pain, gait abnormalities, dysautonomia, non-motor features	LD-related: ↓B12 and ↑HCY & MMA ↑ risk if daily dose > 600 mg/day, > 3 years of treatment, duodopa use Intrinsic: α-synuclein deposition on skin nerve fibres
<i>Paraneoplastic disorders</i>	Serum/CSF CRMP5, Hu, Yo, PCA2, Ma2, DNER, CaSPR2/LGI1	Adult onset	Chorea (CRMP5, Hu) Ataxic tremor (CRMP5, Hu, Yo, PCA2, DNER) Parkinsonism (Ma2) Myotonia (CaSPR2/LGI1)	Axonal pure sensory (50%) or SM (25%), rarely autonomic neuropathy	Limbic encephalitis, cerebellar ataxia, neuropathic pain, dysautonomia Main cancers associated: SCLC (Hu, CRMP5, PCA2), gynaecologic cancer (Yo), male germ cell tumour (Ma2), Hodgkin lymphoma (DNER) Morvan syndrome (CaSPR2/LGI1): neuro-myotonia, cephalopathy, dysautonomia	MRI: often T2/FLAIR hyperintensities (WM, basal ganglia, temporomesial), sometimes diencephalic (Ma2) Neuromyotonic and myokymic discharges on EDX studies (Morvan syndrome)
<i>Autoimmune SLE/APS</i>	Autoantibodies: LAC, cardiolipin, β2-glycoprotein, anti-dsDNA, anti-Sm	Young adult onset	Chorea, dystonia, myoclonus, parkinsonism	Axonal SM, pure motor (rare), small fibre (rare)	Female predominance, multisystemic non-neurological features may be present NPSLE more commonly shows parkinsonism	MRI: T2/FLAIR hyperintensities in the striatum or in the globus pallidus nucleus
<i>Heavy Metals</i>	Manganese, mercury and carbon disulphide	Adult onset	Bradykinesia, rigidity, action tremor and dystonia (Mn) Tremor and ataxia (mercury)	Axonal SM neuropathy	Manganism: “Cock gait” and early behavioural changes at onset Mercury: acute/subacute onset of motor neuropathy (“GBS-like”)	MRI: T1-weighted pallidal signal for Mn intoxication or exposure
<i>Hereditary MDS plus PN syndromes</i>	Gene	Onset	Movement disorder	Neuropathy associated	Peculiar features	Imaging-laboratory findings
<i>Neuroachantocytosis</i>	<i>VPS13A</i> (AR)	Young adult onset	Chorea, parkinsonism, dystonia, tics	Axonal SM	Psychiatric disorders, self-mutilation, seizures (30%), cognitive impairment	Mild–moderate CK elevation in serum, acanthocytes in blood smear
<i>Chorea Acanthocytosis</i>	<i>XK</i> (X-linked)		Chorea, parkinsonism (rare), dystonia (rare)	Axonal SM	Psychiatric disorders, seizures, cardiomyopathy (70%),	MRI: atrophy of caudate ± putamen EDX: myogenic changes
<i>McLeod syndrome</i>						

Table 1 (continued)

Hereditary MDS plus PN syndromes	Gene	Onset	Movement disorder	Neuropathy associated	Peculiar features	Imaging-laboratory findings
<i>Spinocerebellar ataxia</i>	ATXN1 (SCA1), ATXN2 (SCA2), ATXN3 (SCA3), ATXN8 (SCA8), PPP2R2B (SCA12), FGF14 (SCA27)	Adult onset	Chorea, parkinsonism, tremor (postural/intentional), dystonia	Axonal SM or mainly sensory, incidence may be related to CAG repeat expansion	Progressive gait and cerebellar ataxia, eye movement disorder, dysarthria and dysphagia Sometimes additional neurological signs (pyramidal, extrapyramidal, cognitive, peripheral neuropathy)	MRI: cerebellar with or without brainstem atrophy
<i>Wilson disease (WD)</i>	ATP7B gene (AR) ATP7A gene (recessive X-linked; “atypical Menkes disease”)	Young onset	Dysarthria, dystonia, tremor and choreoathetosis	Pure small fibre neuropathy (ATP7B) or axonal neuropathy (ATP7A)	Small fibre neuropathy along with optic neuropathy (ATP7B) Epilepsy, kinky hair, cerebellar ataxia and neurodevelopmental delay (ATP7A: “atypical Menkes disease”)	Main criteria: Kayser–Fleischer rings (KFR) and serum ceruloplasmin (CP) < 10 mg/dL Urinary copper excretion greater than 100 µg per 24 h MRI: T2- weighted hyperintense lesions in the tectal midbrain

AD, autosomal dominant; APS, antiphospholipid antibody syndrome; AR, autosomal recessive; CK, creatine kinase; EDX, electrodiagnostic studies; LAC, lupus anticoagulant; LD, levodopa; MD, movement disorder; NPSLE, neuropsychiatric SLE; PN, polyneuropathy; SCA, spinocerebellar ataxia; SLE, systemic lupus erythematosus; SM, sensorimotor; Mn, manganese; GBS, Guillain-Barré syndrome; WD, Wilson disease

Table 2 Acquired and hereditary peripheral neuropathies associated with MDS

Acquired PN plus MD syndromes	Diagnostic markers	Onset	Neuropathy	Movement disorders	Peculiar features	Imaging–laboratory findings
<i>Chronic acquired demyelinating neuropathy</i>						
<i>Anti-MAG neuropathy</i>	Anti-MAG antibodies IgM gammopathy	Late adult onset	Demyelinating SM	Postural/action tremor Rest tremor (anti-MAG)	Sensory ataxia, mild distal weakness, rarely cerebellar signs	EDX: ↑↑ distal latencies Nerve biopsy: widening of myelin lamellae
<i>CIDP</i>	Anti-NF155 > seronegative	Adult onset	Demyelinating SM	Tremor, ataxia	Anti-NF155 + : sensory ataxia, neuropathic pain, tremor, dysautonomia, cerebellar signs	CSF: albumino-cytologic dissociation MRI: rarely CNS demyelinating lesions
<i>Metabolic</i>						
<i>B12 deficiency</i>	↑ HCY and MMA ↓ B12 levels	Infantile/adult onset	Axonal SM	Chorea, tremor, myoclonus, dystonia	Impaired vibration sense and proprioception, gait ataxia, pyramidal signs, mood disorders, optic atrophy	MRI: T2/STIR hyperintensities posterior ± lateral columns of the cervical and upper thoracic cord Blood: macrocytosis, megaloblastic anaemia
<i>Chronic kidney disease</i>	↑ creatinine and urea	Adult onset	Axonal sensory SM	Asterixis, tremor, myoclonus, parkinsonism	Behavioural disorders, cerebrovascular disease	MRI: rarely lentiform fork sign (parkinsonism)
<i>Hyperosmolar Hyperglycaemia</i>	↑↑↑ glucose	Adult onset	Axonal SM	Chorea/ballism (usually unilateral)	Encephalopathy, altered mental status	Glucose serum level > 400 mg/dL; ketones usually under threshold; hyperuricemia MRI: T2/FLAIR hyperintensity of putamen
<i>Hereditary PN plus MD syndromes</i>	Gene mutated	Onset	Neuropathy	Movement disorders	Peculiar features	Imaging–laboratory findings
<i>Hereditary SM neuropathies</i>						
<i>Charcot–Marie–Tooth disease</i>	PMP22 dupl. (CMT1A, AD), MFN2 (CMT2A, AD), GDAP1 (CMT2K, AR), LRSAM1 (CMT2P, AD/AR), FIG4 (CMT4J, AR), SLC25A46 (CMT6, AR)	Child/adult onset	Demyelinating SM (CMT1, CMT4J) Axonal SM (CMT2, CMT6)	Postural/action tremor (40%), rarely parkinsonism-LR + (LRSAM1, FIG4), dystonia	Optic atrophy (MFN2, SLC25A46)	EDX: non-uniform demyelination (FIG4)
<i>HNPP</i>	PMP22 del. (AD)	Child/adult onset	Demyelinating SM	Tremor, dystonia, myoclonus	Recurrent mononeuropathies due to mild trauma or compression	US: nerve enlargement at entrapment sites
<i>Motor neuron disease</i>						
<i>SBMA</i>	Androgen receptor gene (AR)	Young/adult onset	Axonal sensory	Tremor	Progressive, generalized muscle weakness, including bulbar dysfunction, gynecomastia	EDX: reduced SAPs together with widespread signs of LMN loss

Table 2 (continued)

Acquired PN plus MD syndromes	Diagnostic markers	Onset	Neuropathy	Movement disorders	Peculiar features	Imaging–laboratory findings
<i>Mitochondrial disorders</i>	POLG1 (AD/AR), C10ORF2 (AD/AR), TYMP (AR), MPV17 (AR), COX20 (AR), UQRC1 (AD)	Child/adult onset	Axonal SM Axonal sensory (POLG1, C10ORF2, COX20)	Dystonia, parkinsonism-LR+ Dystonia, chorea, myoclonus (MERRF, MELAS, Leigh syndrome)	Several presentations: —CPEO w/o myopathy —ataxia —neuropathy spectrum disorder —neuropathy + parkinsonism —complex phenotypes (es. SANDO)	↑ lactate and lactate/pyruvate ratio ↑ FGF21 and GDF15 MRI: CNS white matter disease
CANVAS	RFC1 (AR)	Adult onset	Axonal sensory	Bradykinesia, tremor, postural instability, slow saccades, chorea, dystonia	Cerebellar ataxia, sensory neuropathy, bilateral vestibular areflexia, chronic cough, dysautonomia, parkinsonism Overlapping phenotypes with MSA-C and PSP	EDX: sensory neuropathy Abnormal VVOR video-oculography MRI: atrophy of anterior and dorsal vermis, crus I
FXTAS	FMR1 (X-linked)	Young/adult onset	Axonal sensory	Parkinsonism-LR + (60%)	Cerebellar ataxia, nystagmus, dysarthria, dysautonomia, psychiatric symptoms, cognitive impairment	MRI: T2-hyperintensities of middle cerebellar peduncles and splenium of corpus callosum Abnormal ¹²³ I-ioflupane SPECT
<i>Autosomal recessive cerebellar ataxias (ARCAAs)</i>	FXN (Friedreich's ataxia) ATM (AT) APTX (AOA1) SETX (AOA2)	Child > adult onset	Axonal SM	Tremor, dystonia, chorea (rare)	combination of areflexia and extensor plantar responses, cerebellar ataxia, oculomotor apraxia, cutaneous telangiectasias, immunodeficiency, cancer predisposition	↑ Serum AFP (AT, AOA1, AOA2) MRI: cerebellar atrophy Hypoalbuminemia and hypercholesterolemia (AOA1)
<i>Hereditary spastic paraplegias (HSPs)</i>	Paraplegin (SPG7, AR) KIF5A (SPG10, AD) Spatacsin (SPG11, AR) Spastizin (SPG15, AR) KIF1A (SPG30,### AD)	Child/adult onset	Axonal SM	Parkinsonism, dystonia	Slowly progressive, symmetric, spastic paraparesis, urinary disturbances, impaired vibration sense Complex phenotypes with additional peripheral neuropathy, extrapyramidal, cerebellar and cognitive deficits	MRI: thin corpus callosum (SPG11), cerebellar/brain atrophy Abnormal central motor conduction on motor-evoked potentials

AD, autosomal dominant; AFP, alpha-fetoprotein; AR, autosomal recessive; AT, ataxia-telangiectasia; CIDP, chronic inflammatory demyelinating polyneuropathy; CMT, Charcot-Marie-Tooth; CNS, central nervous system; HCY, homocysteine; LMN, lower motor neuron; LR+, levodopa responsive; MD, movement disorder; MERRF, myoclonic epilepsy with ragged red fibres; MELAS, mitochondrial encephalomyopathy, lactic acidosis and stroke-like episodes; MMA, methylmalonic acid; PN, polyneuropathy; SAPs, sensory action potentials; SM, sensorimotor; VVOR, visually enhanced vestibulo-ocular reflex

pathogenesis in these individuals [9]. This mechanism is supported by evidence that COMT inhibitors, which halt methylation of levodopa, were linked to higher vitamin B12 levels and lower neurotoxic metabolites [10]. A dose-dependent levodopa neurotoxicity was further supported by the description of PD patients on duodopa therapy, who may develop a chronic symptomatic PN or more rarely a subacute, severe, axonal neuropathy with tetraparesis resembling Guillain–Barré syndrome [11–14]. Multiple vitamin B deficiencies (B1, B6, B12) have been advocated as the trigger of this subacute neuropathy and their supplementation improves neuropathic symptoms [9]. Periodic Hcy, vitamin B12 and folate screening, together with serial clinical and neurophysiological assessment, may be advisable in patients receiving > 600 mg/day dose levodopa and in those treated for more than 3 years or on duodopa therapy. Rarely, autosomal-recessive juvenile parkinsonism due to *parkin* mutations may show a predominant sensory or sensorimotor neuropathy, which may precede overt parkinsonism [15, 16]. Beside levodopa therapy, an intrinsic, PD-related neurodegenerative process affects the peripheral nervous system, presenting as a small fibre neuropathy (SFN) leading to sensory and autonomic impairment [17, 18]. The clinical features (i.e. pinprick and thermal sensory loss, burning pain, hyperalgesia and allodynia), associated with abnormal selected investigations (i.e. quantitative sensory testing, laser-evoked potentials) [19] and normal conduction studies suggest a diagnosis of SFN. Pathological confirmation is generally required with evidence of a reduced intraepidermal nerve fibre density (IENFD) on skin biopsy, which has been detected in several cohorts of PD patients. About 60–70% of PD patients suffer from mild to moderate autonomic dysfunction such as orthostatic hypotension, bladder and bowel disturbances, sudomotor abnormalities and sexual dysfunction due to small fibre involvement [20]. An intrinsic pathology is supported by evidence of α -synuclein deposition in the skin and sensory nerve fibres of both sporadic and genetic PD patients [21–25], raising as a potential biomarker for early diagnosis. A peripheral α -synuclein deposition in the skin has also been demonstrated in other α -synucleinopathies such as Lewy body dementia [26] and multiple system atrophy (MSA) [27], proving skin biopsy to be a valuable tool for the distinction of parkinsonism related to synucleinopathies compared to tauopathies, including progressive supranuclear palsy (PSP) and corticobasal degeneration (CBD) [27].

Paraneoplastic disorders

Neurological manifestations in cancer are common, disabling and often underdiagnosed. The concomitant presence of a specific movement disorder associated with neuropathy may be the result of a paraneoplastic syndrome, and unmasking the underlying malignancy proves effective for

the resolution of neurologic symptoms. Choreic movements and peripheral neuropathy are associated, respectively, with 11% and 42% of CRMP5-IgG antibodies paraneoplastic syndromes as part of a more extensive involvement of the nervous system that may include limbic encephalitis and cerebellar ataxia [28]. Peripheral neuropathy precedes the cancer diagnosis in more than 90% of cases; axonal sensorimotor neuropathy is more frequent than pure sensory neuropathy (50% vs. 25%). Dysautonomia is uncommon. Small cell lung cancer (SCLC), the most common malignancy, is diagnosed in 75% of CRMP5-IgG paraneoplastic syndromes and thymoma in 15% of the cases. Clinical manifestation associated with ANNA1/anti-Hu antibodies in SCLC are ataxia, choreoathetoid movements, dystonia and a sensory neuronopathy with neuropathic pain and ataxia due to degeneration of the dorsal root ganglia neurons [29]. Dysautonomia is present in more than 70% of cases. In anti-Ma2 encephalitis, neuropathy is often associated with parkinsonian features such as bradykinesia, masked faces, hypophonia and rigidity; tremor is less frequent [30]. In male patients up to 50 years, there is a strong association with germ cell tumours of the testis [31]. In women and in men more than 50 years, the associated tumours include non-SCLC, breast cancer, colon cancer and lymphoma. Ataxia associated with neuropathy has been described in patients with Hu-Ab and PCA2-Ab and SCLC, Yo-Ab and gynaecologic cancers, DNER-Ab and Hodgkin lymphoma [32, 33]. Neuromyotonia, peripheral neuropathy, hyperhidrosis, tachycardia, insomnia and urinary dysfunction, especially in males, are typical of Morvan's syndrome [34]. Needle EMG examination detects myotonic discharges, with the characteristic wax and wane pattern. When associated with neoplasms, especially thymoma, CASPR2 and LGL1 should be investigated for [35].

Autoimmune disorders

Although peripheral neuropathy in antiphospholipid syndrome (APS) and systemic lupus erythematosus (SLE) underlies immune and vascular mechanisms [36], the pathophysiology of movement disorders is not completely understood, and multiple mechanisms may play a role. Classically, antiphospholipid antibody–antigen complex affects coagulation to result in thrombosis. Some patients who develop movement disorders in the context of APS and SLE have ischaemic-appearing lesions on neuroimaging [37]; however, in the majority of them, there are no specific imaging findings suggesting a different aetiology. Chorea is the most common movement disorder in APS and SLE, with a prevalence between 1 and 4.3% [38–40]. Men are scarcely involved. In most cases, the episode is single, the onset bilateral and the prognosis good, but sometimes there may be relapses (2–6 episodes). Immunologic testing often reveals positive lupus anticoagulant and anticardiolipin antibodies

in blood. Less frequent manifestations are ataxia, dystonia and myoclonus. A sensorimotor axonal polyneuropathy is diagnosed in approximately 6% of patients with SLE, while rarely it may present with isolated motor involvement [41]. Small fibre involvement is uncommon [42]. Moreover poorly levodopa-responsive parkinsonism is more often associated with neuropsychiatric lupus (NPSLE), both in patients with an established diagnosis of SLE and as a presenting subacute manifestation of NPSLE [43]. Parkinsonism associated with peripheral neuropathy has been also described in Sjogren's syndrome and rheumatoid arthritis, both due to a prothrombotic aetiology [44]. In most cases, brain MRI shows hyperintensity on T2 and FLAIR in the striatum or in the globus pallidus nucleus.

Heavy metals

A number of heavy metals have been described in association with parkinsonism and neuropathy, comprising manganese (Mn), mercury and carbon disulphide (CS₂; Table 1).

In particular, the exposure to high concentrations of Mn dust and fumes in mining workers leads to an increased risk of manganism, defined as a complex clinical entity characterized by parkinsonism, behavioural changes and neuropathy [45–47]. Mn crosses the blood–brain barrier and accumulates in the mitochondria within the globus pallidus [48]. Patients usually develop bradykinesia, rigidity, action tremor and dystonia, more pronounced in the lower limbs, leading to the typical “cock gait” [46]. The therapeutic effect of levodopa is usually unsatisfactory and the disease rapidly evolves within 5 years [49]. Conversely, neuropathy may arise either from a direct effect or by disrupting the dopaminergic modulation of thyroid hormone synthesis, likely accounting also for neurodevelopmental effects as observed in chronic Mn exposure [50].

Conversely, mercury is usually associated with hyperkinetic features (tremor, ataxia) and a subacute sensory and motor neuropathy, closely mimicking Guillain–Barré SYNDROME and acute axonal polyneuropathies [51] (Table 1).

Hereditary MDS with neuropathy

Neuroacanthocytosis

Core neuroacanthocytosis syndromes (NA syndromes) encompasses a heterogeneous group of genetic syndromes characterized by the coexistence of acanthocytes on blood smear and neurological symptoms. Among them, the so-called “core” NA syndromes are characterized by movement disorders due to basal ganglia degeneration, peripheral nervous system involvement, cognitive impairment and psychiatric features. However, only chorea acanthocytosis (ChAc) and McLeod syndrome (MLS) show extrapyramidal features

along with a peripheral involvement. Patients with ChAc, caused by VPS13A gene mutation, develop generalized chorea in the majority of cases and parkinsonism in the minority [52]. Other extrapyramidal features in these patients include peculiar “feeding dystonia” with tongue protrusion, orofacial dyskinesias limb and trunk dystonia [53]. Even if most patients have neuromuscular involvement, myopathic changes are rare at EMG examination despite muscle atrophy, weakness and a typical elevation of creatine phosphokinase (CK) [54]. Axonal neuropathy is frequent, but usually mild to moderate. MLS is defined as the absence of Kx red blood cell (RBC) protein and weak expression of Kell antigens on RBCs. Compared to ChAc, MLS is characterized by more consistent neuromuscular manifestations due to a severe myopathic and axonal neuropathic involvement. In most cases CK elevation is severe, however, typically < 4000 U/L [55, 56]. Patients usually develop chorea, while parkinsonism and dystonia are uncommon. Generalized seizures occur in about half of the patients. MLS presents in young-to-middle adulthood, even though MLS typically has a later onset of neurological symptoms.

Spinocerebellar ataxias

Spinocerebellar ataxias (SCAs) represent progressive, autosomal dominant, neurodegenerative disorders involving the cerebellum-connected structures. Even though ataxia is the main feature in most cases, different phenotypes can be observed in the same SCA subtype due to the combined involvement of the brainstem, spinal cord and peripheral nervous system [57]. The coexistence of extrapyramidal symptoms and peripheral neuropathy is typical of numerous SCA subtypes. SCA can manifest as parkinsonism, especially in SCA2, SCA3 and SCA17, closely mimicking idiopathic PD, thus representing a not uncommon genetic cause of parkinsonism, even in apparently sporadic cases [58]. Dystonia is usually associated with it. Since mutation of SCA genes is considered positive in 0.5–8% of familial PD [59–61], the screening of SCA2, SCA3 and SCA17 is required in PD patients. Small expansions with interruption could explain the parkinsonian phenotype and genetic cases with relatively low penetrance. SCA3 is common in Western populations, while SCA2 and SCA17 are predominant in Asian populations; however, a sensory axonal mild polyneuropathy has been described only in SCA2 and SCA3, respectively, in 80% and 54% of patients. In SCA3, the fewer the CAG repetitions, the more is the peripheral involvement. Tremor is associated with polyneuropathy in SCA2, SCA8, SCA12 and SCA27. Tremor can be (a) a fast (6.5–8 Hz) action, postural or orthostatic tremor, becoming slower over time in case of association with parkinsonism or (b) slow action and intention tremor (3–4 Hz). Different features in SCA-related tremor likely depend on which

pathway is mainly involved: the cerebello-thalamo-cortical loop or nigro-striatal dopaminergic pathway [62]. Chorea is uncommon, described mainly in SCA1 and SCA17. Since the more the CAG repetitions, the more is the disease severity in the SCA1 subtype, and co-presence between chorea and sensorimotor axonal polyneuropathy is not uncommon.

Inborn errors of copper metabolism: Wilson disease (WD)

Wilson disease (WD) is an autosomal-recessive disease caused by mutations in the *ATP7B* gene, encoding a copper-transporting ATPase, and clinically characterized by dysarthria, dystonia, tremor (the “wing-beating tremor”) and choreoathetosis [63, 64]. As the main criteria, the presence of Kayser–Fleischer rings (KFR) and serum ceruloplasmin (CP) < 10 mg/dL are sufficient per se to confirm the diagnosis [64]. A more detailed description of WD is beyond the aim of our paper, but sometimes mutations in a second, closely related copper-transporting ATPase, formally named *ATP7A*, induces a distal motor neuropathy (see Table 1). Although very rare, this neuropathic involvement can present alone, predominantly as a small fibre disease [65, 66], or along with an “atypical Menkes disease”, also comprising epilepsy, kinky hair, cerebellar ataxia and neurodevelopmental delay [67].

Neuropathy with MDS

Tremor is the most common movement disorder observed in patients with peripheral neuropathies, for whom the label neuropathic tremor is frequently used. It presents as a postural/action tremor, bilateral, commonly affecting the distal upper limbs and impairing the common activities of daily life, such as handwriting and drinking. It is more commonly observed in chronic demyelinating neuropathies rather than axonal neuropathies, as well as in patients with concomitant cerebellar dysfunction. Other movement disorders, such as dystonia, parkinsonism and myoclonus may be present in patients with other neuropathies, either acquired or inherited, usually in the context of complex disease phenotypes.

Sporadic neuropathies with MDS

Chronic acquired demyelinating neuropathies

Neuropathic tremor is a prevalent feature in chronic acquired demyelinating neuropathies, such as paraproteinemic (IgM) polyneuropathy, with or without anti-myelin-associated glycoprotein (MAG) antibodies, chronic inflammatory demyelinating polyneuropathy (CIDP) and also multifocal motor neuropathy (MMN) with conduction blocks. Rarely, it rather occurs later in the disease course, with studies showing a

median time interval from disease onset of 5.8 years [68]. Paraproteinemic IgM-associated neuropathy classically presents as a chronic progressive distal demyelinating neuropathy affecting mainly sensory function, with ataxia, distal sensory loss and mild lower limb muscle weakness being the main symptoms [69]. Neuropathic tremor is a classic feature, affecting up to 90% of cases and can be severely disabling in almost half of the cases with long-standing disease [68, 70]. Rarely, an additional resting component has been reported in patients with positive anti-MAG titres. Interestingly, detailed clinical and neurophysiological assessment revealed that a postural/action tremor may be found in more than half of the patients with CIDP or MMN [68]. Among CIDP subtypes, those with positive antibodies against neurofascin-155 (NF155) represent about 4–18% of cases and show a peculiar phenotype characterized by sensory ataxia, tremor, neuropathic pain, autonomic and cranio-bulbar symptoms, sometimes associated with signs of cerebellar dysfunction (cerebellar ataxia, dysarthria, gaze-evoked nystagmus) and CNS demyelinating lesions [71–73]. Such diverging features led some authors to consider anti-NF155-associated demyelinating neuropathy as a separate disease entity, called “autoimmune nodopathy” [74], although the issue is still controversial. The pathogenesis of tremor in inflammatory neuropathies is poorly understood. Several studies failed to prove the correlation between tremor and other neuropathic features, such as proprioceptive loss or weakness [75, 76]. Nonetheless, despite no association with its occurrence, neurophysiological parameters of demyelination, such as slowed conduction velocities and prolonged distal and F-wave latencies, correlate with tremor severity [68, 77], suggesting the temporal dispersion of afferent inputs may be a necessary, but not sufficient condition to explain the phenomenology of neuropathic tremor. Interestingly, some studies showed that cerebellar dysfunction, as assessed through either through neurophysiological or imaging studies, may further underlie tremor pathogenesis in inflammatory neuropathies [78, 79]. Cerebellar ataxia may indeed be found in inflammatory neuropathies with sensory predominant phenotypes, such as in those with positive anti-NF155 and anti-MAG antibodies, the latter reported also in patients with isolated, late-onset cerebellar ataxia [80]. Lending support to these findings, genetic studies showed that patients with biallelic mutations in either the neurofascin or *MAG* genes are associated with early-onset cerebellar ataxia and demyelinating neuropathy, sometimes with additional manifestations, such as spasticity, myoclonus or dystonia [81, 82]. Besides tremor, other movement disorders have been rarely reported. Of note, a small case series described four patients with MMN, showing pathologic involuntary movements such as muscle spasms and abnormal posturing of the affected limb. Arguing against dystonia, there was an absence of classic features such as specific triggers and sensory tricks, as well as the strict link

between the distribution of abnormal movements and sites of focal conduction block. This led the authors to define these clinical signs as “pseudo-dystonia”, probably due to local axonal hyperexcitability caused by loss of myelin sheath, a mechanism already known to cause other hyperexcitability-related symptoms, such as cramps and fasciculations [83].

Nutritional and metabolic disorders

Acquired toxic-metabolic disorders, typically associated with peripheral neuropathy, may show unusual presentations, including movement disorders. Vitamin B12 deficiency, commonly caused by dietary habits or malabsorption, may present with a myriad of neurologic manifestations [84]. Low vitamin B12 levels are diagnostic, but an increase in homocysteine and/or methylmalonic acid levels may precede overt B12 deficiency on routine laboratory tests [85]. Lack of vitamin B12 results in impaired myelination and axonal degeneration of long tract fibres, leading to a spectrum of clinical disorders ranging from sensorimotor axonal polyneuropathy to a subacute combined degeneration (SCD) involving the posterior and lateral columns. An acute/subacute onset of impaired vibration sense and proprioception in the legs with an ascending fashion resulting in sensory impairment and gait ataxia, together with pyramidal signs, is a classic clinical phenotype [86]. On MRI, T2 hyperintensities in the posterior columns of the cervical and upper thoracic cord may be diagnostic of SCD. Other classic findings may be cognitive and behavioural abnormalities, mood disorders and optic atrophy. Involuntary movements are rarely described in adults with vitamin B12 deficiency, including chorea, tremor, myoclonus and dystonia and may be found in combination with other B12-related manifestations, such as peripheral neuropathy, cognitive impairment or long tract signs [87, 88]. Depletion of vitamin B12 stores in the newborns, such as in those breastfed by B12-deficient mothers, may result in infantile tremor syndrome, a complex and severe disease characterized by developmental delay, lethargy, seizures and tremor, which may be reversible after cobalamin supplementation [88]. While diabetic peripheral neuropathy is the most prevalent complication of type 2 diabetes mellitus with an estimated prevalence that ranges from 21.3 to 34.5% [89], movement disorders are extremely rare. Transient chorea–ballism is a rare complication of non-ketotic hyperglycaemia with an estimated prevalence of less than 1:100,000 [90]. In patients with decompensated diabetes, chorea/ballism, especially when occurring acutely and unilaterally, may mimic a stroke episode (and go into thrombolysis). According to a meta-analysis [91], the mean serum glucose level upon admission is higher than 400 mg/dL. The presentation is unilateral in 88% of patients and prognosis is often good. MRI shows hyperintensity of the putamen nucleus, both unilateral and bilateral. Chronic kidney disease

commonly causes an axonal sensory neuropathy, due to the accumulation of toxic metabolites crossing the blood–nerve barrier [92]. Nonetheless, CNS toxicity may be observed in the acute setting leading to uremic encephalopathy, characterized by altered mental status, behavioural abnormalities, tremor, asterixis and myoclonic jerks. A reversible parkinsonism associated with the lentiform fork sign on MRI may be an unusual manifestation of uremic encephalopathy [93].

Medication-induced disorders

Finally, medications may be responsible for a combined presentation of peripheral neuropathy and involuntary movements. Drugs such as amiodarone and traditional chemotherapeutics are common iatrogenic causes of peripheral neuropathy [94]. In some patients, toxicity may also present with a postural/action tremor, affecting up to a third of patients on long-term amiodarone treatment [95]. Rarely, chemotherapy may result in a levodopa-responsive parkinsonism, which may be reversible after suspension of treatment [96].

Hereditary neuropathies with MDS

Hereditary sensory and motor neuropathies

Hereditary motor and sensory neuropathies (HSMN), also known as Charcot–Marie–Tooth (CMT) disease, comprise a group of heterogenous disorders characterized by juvenile- or adult-onset peripheral neuropathy with slowly progressive distal amyotrophy, areflexia and sensory deficits. Various movement disorders have been described in the context of HSMN, such as tremor, parkinsonism and dystonia. A postural/action tremor in the upper limbs is commonly observed in patients with long-standing HSMN, reported in up to 40% of cases with CMT1A [97], the most common type of demyelinating CMT caused by duplication of the *PMP22* gene. Furthermore, patients with axonal CMT (CMT2) may be tremulous, as up to 20% of cases with *MFN2* or *GDAP1* mutations may show hand tremor [98]. Tremor presentation is usually delayed compared to neuropathy onset, with a time lag of several years. It has apparently no relationship with the degree of muscle weakness and sensory deficits and a central mechanism has been suggested [97]. In comparison, parkinsonism is rare, although it has been reported in some HSMN patients with mutations in *LRSAM1* [99], *FIG4* [100, 101] and *SLC25A46* [102] genes. In such cases, patients present with a juvenile- or adult-onset slowly progressive neuropathy, while parkinsonism either appears simultaneously or follow after a few years, being potentially responsive to levodopa treatment. Some clinical clues may help to clinch the diagnosis in such patients. For example, patients with early-onset parkinsonism and demyelinating neuropathy may suggest autosomal-recessive *FIG4* mutations, further

supported by the presence of a non-uniform demyelination in neurophysiological studies, resembling acquired demyelinating neuropathies [100]. The combination of a sensorimotor axonal neuropathy together with optic atrophy and parkinsonism/dystonia may point towards pathogenic variants in the *SLC25A46*, which encodes for a mitochondrial carrier protein involved in mitochondrial dynamics and responsible for a broad spectrum of neurodegenerative diseases, ranging from lethal congenital pontocerebellar hypoplasia (PCH) to the mildest phenotypes including optic atrophy, peripheral neuropathy, cerebellar ataxia and spasticity [102, 103]. Few reports have also described an association between movement disorders and other hereditary neuropathies, comprising hereditary neuropathy with liability pressure palsies (HNPP) and distal hereditary motor neuropathy (dHMN). Tremor, dystonia and myoclonus have been rarely reported in HNPP patients [104–106], primarily involving the limbs affected by pressure palsies then spreading over adjacent segments, suggesting the presence of an additional central mechanism responsible for the abnormal movements. Finally, mutations in the *DCTN1* gene are responsible for several neurological disorders including CMT, dHMN-type VIIB, ALS and Perry syndrome, an adult-onset neurodegenerative disorder characterized by neuropsychiatric symptoms, parkinsonism and central hypoventilation. Recently, a common missense mutation has been reported in a large family pedigree presenting with either dHMN-VIIB or Perry syndrome, with some members showing overlapping features [107].

Motor neuron diseases

More rarely, lower motor neuron diseases have also been associated with concomitant peripheral neuropathy and CNS manifestations. For example, spinal and bulbar muscular atrophy (SBMA), also known as Kennedy's disease, is a progressive lower motor neuron disorder caused by a CAG repeat expansion in the androgen receptor gene. A peripheral nerve involvement with small or absent SAPs is frequently encountered and highly diagnostic for SBMA [108]. Although rarely reported, tremor is the most common CNS manifestation of SBMA and is associated with other neurological features, such as cognitive impairment and white matter abnormalities in neuroimaging studies [109].

Mitochondrial disorders

Mitochondrial diseases (MIDs) represent a group of inherited neurometabolic disorders characterized by mitochondrial dysfunction and failure in multiple tissues, including the brain, peripheral nerves, muscle, heart, and visual and auditory pathways. Clinical phenotypes are highly heterogeneous, ranging from isolated manifestations, such as chronic

progressive external ophthalmoplegia (CPEO) and myopathy, to multiple syndromic features, with variable combinations of psychomotor delay, epilepsy, CPEO, myopathy, neuropathy, optic atrophy, movement disorders, sensorineural hearing loss and stroke-like episodes [110, 111]. Peripheral neuropathy may be the predominant feature in selected MIDs, such as those associated with mutations in nuclear genes including *POLG1*, *C10ORF2*, *TYMP* and *MPV17* [98]. *POLG* mutations are responsible for 10–25% of MIDs cases [112–115], commonly presenting with an adult-onset CPEO or showing early-onset multisystemic disorders, such as Alpers–Huttenlocher syndrome and mitochondrial recessive ataxia syndrome. *POLG* mutations are typically associated with a moderate-to-severe predominantly sensory axonal neuropathy, resulting in sensory loss, ataxia and neuropathic pain [98, 114]. Sensory neuronopathy is characteristic of *POLG*-related diseases and may also be found in more complex phenotypes such as sensory ataxic neuropathy, dysarthria and ophthalmoparesis (SANDO) or ataxia neuropathy spectrum. Sometimes, movement disorders such as dystonia and parkinsonism may present later in the disease course in patients with *POLG* mutations [116–118], usually mimicking classic PD with an asymmetric tremor-predominant form, presynaptic dopaminergic deficits on neuroimaging and response to levodopa. Parkinsonism may also be encountered in patients mutated in the *C10ORF2*, who frequently show a sensory-predominant neuropathy similar to *POLG*-related diseases [98]. Mutations in *COX20* gene leads to mitochondrial complex IV deficiency, which manifests with early-onset cerebellar ataxia, sensory neuropathy and dystonia [119]. Recently, the mitochondrial *UQCRC1* gene was found as a new cause of autosomal-dominant parkinsonism and polyneuropathy [120]. Peripheral neuropathy is common also in other MIDs, often sensory or sensorimotor and subclinical, representing a minor feature of more complex disorders, as it occurs in myoclonic epilepsy with red-ragged fibres (MERRF), Leigh syndrome, mitochondrial myopathy, encephalopathy, lactic acidosis and stroke-like episodes (MELAS), and Kearns–Sayre syndrome, which usually present during childhood or early adulthood [98, 121]. In such cases, dystonia is the most common movement disorder observed, usually generalized, followed by myoclonus and chorea while parkinsonism is rare [118].

Cerebellar ataxia, neuropathy and vestibular areflexia syndrome

Peripheral neuropathy and movement disorders may also coexist in other hereditary disorders with common neuropathic features, although other neurological signs predominate the clinical picture, such as ataxia or spasticity. The discovery of a biallelic intronic (AAGGG)_n expansion in the replication factor C subunit 1 (*RFC1*) gene as the major

cause of cerebellar ataxia, neuropathy and vestibular areflexia syndrome (CANVAS, 90% of cases) and late-onset cerebellar ataxia (from 6 to 22%) was a recent breakthrough in the field of adult-onset cerebellar ataxias [122–124]. CANVAS is a neurodegenerative disorder manifesting as a slowly progressive gait ataxia, beginning in the fifth to sixth decades, associated with a clinical or neurophysiological evidence of a sensory neuropathy/neuronopathy and bilateral vestibular areflexia [125]. A sensory neuronopathy is a major feature of the disease, detected in 100% of cases, and may be the sole clinical presentation, followed by a stepwise progression with vestibular and cerebellar dysfunction [124]. Loss of vibration sense and proprioception contribute to gait ataxia, while a clinical–electrodiagnostic dissociation may be observed between sensory symptoms, such as tingling, numbness and neuropathic pain, and the degree of axonal loss, with generalized loss of sensory action potentials in about half of the cases [126]. Vestibular areflexia can be witnessed by an abnormal head impulse test or video-oculography [127] and usually manifests with oscillopsia and non-specific visual disturbances, while vertigo is rare [124]. Patients with a biallelic *RFC1* expansion more commonly develop a multisystemic disorder in which gait ataxia can be accompanied by autonomic dysfunction (62%) as well as extrapyramidal symptoms, such as bradykinesia, postural instability and slow vertical saccades, presenting overlapping phenotypes with either MSA-C or PSP in 19% and 9%, respectively [128]. Interestingly, genetic screening of the *RFC1* expansion identified positive patients also in non-CANVAS cohorts, such as those with idiopathic sensory neuropathy (up to a third) [126] and rarely as a pure parkinsonism indistinguishable from idiopathic PD [129].

Fragile X tremor/ataxia syndrome

Fragile X tremor/ataxia syndrome (FXTAS) is a rare late-onset neurodegenerative disorder due to the presence of a premutation size of 55–200 CGG repeat expansion in the fragile X mental retardation 1 (*FMR1*) gene. Core clinical features are cerebellar ataxia, tremor and nystagmus, but a great phenotypic variability is appreciated, with studies reporting a high prevalence of sensory neuropathy (up to 80%) and parkinsonism in 60% of cases, accompanied by abnormal dopaminergic transport deficits and response to levodopa [130, 131]. Importantly, up to 25% of cases may be initially diagnosed with idiopathic parkinsonism, although the presence of an underlying sensory neuropathy, which could be either non-length dependent (56%) or length dependent (25%), should alert the clinician towards an alternative diagnosis, including FXTAS [131]. Other characteristic features are autonomic dysfunction and psychiatric and cognitive abnormalities, frequently accompanied by radiological signs such as T2-hyperintensities of the middle

cerebellar peduncles and splenium of the corpus callosum [132].

Autosomal-recessive cerebellar ataxias

The combination of cerebellar ataxia and a dorsal root ganglionopathy or polyneuropathy is an important diagnostic clue also for autosomal-recessive cerebellar ataxias (ARCAs), such as Friedreich's ataxia (FA), ataxia-telangiectasia (AT) and ataxia with oculomotor apraxia 1 and 2 (AOA1 and AOA2). They can be recognized in cases showing an early age of onset (usually < 20 years) and peculiar signs, such as the combination of areflexia and extensor plantar responses (FA) or the combination of oculomotor apraxia and high levels of alpha-fetoprotein (AT, AOA1, AOA2) [133–135]. Furthermore, the presence of cutaneous telangiectasias, recurrent infections and sensitivity to ionizing radiation are essential clues for the diagnosis of AT [133]. Hyperkinetic movements, such as tremor, dystonia and chorea may be additional signs in these patients, although rarely observed in adult-onset cases [136–139].

Hereditary spastic paraplegias

Hereditary spastic paraplegias (HSPs) are a group of hereditary disorders characterized by lower limb weakness and spasticity. Both uncomplicated and complicated forms, with additional neurological signs, may occur and detect in many genetic HSP subtypes. Peripheral neuropathy is the most common non-pyramidal abnormality found in HSP [140], with axonal forms commonly described in both autosomal-dominant (SPG3A/atlastin, SPG6/*NIPA1*, SPG10/*KIF5A*, SPG30/*KIF1A*) and autosomal-recessive HSPs (SPG7/paraplegin, SPG11/spatacsin, SPG15/spastizin, SPG48/*AP5Z1*) [140–142], while demyelinating forms were only reported in autosomal-recessive SPG75 due to biallelic null *MAG* mutations [143]. Among these subtypes, extrapyramidal symptoms, including a dopa-responsive parkinsonism or dystonia, may occur in the context of multisystemic phenotypes, especially in cases with SPG7, SPG11, SPG15 [141, 144–146] as well as those with mutations in the kinesin genes, such as SPG10 and SPG30 [147, 148].

Conclusions

Movement disorders and peripheral neuropathy may coexist in several neurological disorders and both acquired and genetic causes should be accounted for. A careful neurological examination is necessary to identify multisystem pathology, as well the search for extra-neurological features, involving the skin, bones, heart and special senses, such as vision and hearing. Raising awareness of this potential

relationship may help clinicians to unravel the final diagnosis and guide clinical management.

Author contributions Conceptualization, T.B. and F.G.; methodology, F.G. and A.B.; validation, T.B. and A.P.; formal analysis, investigation, and resources F.G. and A.B.; data curation, F.G. and A.B.; writing—original draft preparation, F.G. and A.B.; writing—review and editing, T.B. and A.P.; visualization and supervision, T.B.; funding acquisition, T.B. and A.P. All authors have read and agreed to the published version of the manuscript.

Declarations

Conflicts of interest The authors declare that they have no conflict of interest.

References

- Reimann J, Paus S (2017) Movement disorders hidden in the neuromuscular clinic. *Neuromuscul Disord* 27:S243
- Bloem BR, Voermans NC, Aerts MB, Bhatia KP, van Engelen BG, van de Warrenburg BP (2016) The wrong end of the telescope: neuromuscular mimics of movement disorders (and vice versa). *Pract Neurol* 16:264–269
- Zis P, Grunewald RA, Chaudhuri RK, Hadjivassiliou M (2017) Peripheral neuropathy in idiopathic Parkinson's disease: a systematic review. *J Neurol Sci* 378:204–209
- Beaulieu ML, Muller M, Bohnen NI (2018) Peripheral neuropathy is associated with more frequent falls in Parkinson's disease. *Parkinsonism Relat Disord* 54:46–50
- Corra MF, Vila-Cha N, Sardoeira A, Hansen C, Sousa AP, Reis I, Sambayeta F, Damasio J, Calejo M, Schicketmueller A, Laranjinha I, Salgado P, Taipa R, Magalhaes R, Correia M, Maetzler W, Maia LF (2022) Peripheral neuropathy in Parkinson's disease: prevalence and functional impact on gait and balance. *Brain*. <https://doi.org/10.1093/brain/awac026>
- Ceravolo R, Cossu G, Bandettini di Poggio M, Santoro L, Barone P, Zibetti M, Frosini D, Nicoletti V, Manganelli F, Iodice R, Picillo M, Merola A, Lopiano L, Paribello A, Manca D, Melis M, Marchese R, Borelli P, Mereu A, Contu P, Abbruzzese G, Bonuccelli U (2013) Neuropathy and levodopa in Parkinson's disease: evidence from a multicenter study. *Mov Disord* 28:1391–1397
- Toth C, Breithaupt K, Ge S, Duan Y, Terris JM, Thiessen A, Wiebe S, Zochodne DW, Suchowersky O (2010) Levodopa, methylmalonic acid, and neuropathy in idiopathic Parkinson disease. *Ann Neurol* 68:28–36
- Rajabally YA, Martey J (2011) Neuropathy in Parkinson disease: prevalence and determinants. *Neurology* 77:1947–1950
- Paul DA, Qureshi ARM, Rana AQ (2020) Peripheral neuropathy in Parkinson's disease. *Neurol Sci* 41:2691–2701
- Lamberti P, Zoccollella S, Iliceto G, Armenise E, Fraddosio A, de Mari M, Livrea P (2005) Effects of levodopa and COMT inhibitors on plasma homocysteine in Parkinson's disease patients. *Mov Disord* 20:69–72
- Galazky I, Schoof J, Stallforth S, Kupsch A, Heinze HJ, Kluge C (2014) Guillain-Barre/CIDP-like neuropathy in two parkinsonian patients following intestinal levodopa/carbidopa treatment. *Parkinsonism Relat Disord* 20:125–127
- Manca D, Cossu G, Murgia D, Molari A, Ferrigno P, Marcia E, Melis M (2009) Reversible encephalopathy and axonal neuropathy in Parkinson's disease during duodopa therapy. *Mov Disord* 24:2293–2294
- Merola A, Romagnolo A, Zibetti M, Bernardini A, Cocito D, Lopiano L (2016) Peripheral neuropathy associated with levodopa-carbidopa intestinal infusion: a long-term prospective assessment. *Eur J Neurol* 23:501–509
- Urban PP, Wellach I, Faiss S, Layer P, Rosenkranz T, Knop K, Weis J (2010) Subacute axonal neuropathy in Parkinson's disease with cobalamin and vitamin B6 deficiency under duodopa therapy. *Mov Disord* 25:1748–1752
- Domingos J, Coelho T, Taipa R, Basto JP, Melo-Pires M, Magalhaes MJ (2015) PARK2 presenting as a disabling peripheral axonal neuropathy. *Neurol Sci* 36:341–343
- Okuma Y, Hattori N, Mizuno Y (2003) Sensory neuropathy in autosomal recessive juvenile parkinsonism (PARK2). *Parkinsonism Relat Disord* 9:313–314
- Jeziorska M, Atkinson A, Kass-Iliyya L, Javed S, Kobylecki C, Gosal D, Marshall A, Silverdale M, Malik RA (2019) Increased intraepidermal nerve fiber degeneration and impaired regeneration relate to symptoms and deficits in Parkinson's disease. *Front Neurol* 10:111
- Nolano M, Provitera V, Manganelli F, Iodice R, Stancanelli A, Caporaso G, Saltalamacchia A, Califano F, Lanzillo B, Picillo M, Barone P, Santoro L (2017) Loss of cutaneous large and small fibers in naive and l-dopa-treated PD patients. *Neurology* 89:776–784
- Themistocleous AC, Ramirez JD, Serra J, Bennett DL (2014) The clinical approach to small fibre neuropathy and painful channelopathy. *Pract Neurol* 14:368–379
- Xu X, Liao J, Dong Q, Qin F, Li J, Sun X, Lu T, Fang L, Peng F, Lu Z, Qiu W (2019) Clinical utility of SUDOSCAN in predicting autonomic neuropathy in patients with Parkinson's disease. *Parkinsonism Relat Disord* 64:60–65
- Carmona-Abellan M, Gabilondo I, Murueta-Goyena A, Khurana V, Tijero B, Luquin MR, Acera M, Del Pino R, Gardeazabal J, Martinez-Valbuena I, Sanchez-Pernaute R, Gomez-Esteban JC (2019) Small fiber neuropathy and phosphorylated alpha-synuclein in the skin of E46K-SNCA mutation carriers. *Parkinsonism Relat Disord* 65:139–145
- Donadio V, Incensi A, Leta V, Giannoccaro MP, Scaglione C, Martinelli P, Capellari S, Avoni P, Baruzzi A, Liguori R (2014) Skin nerve alpha-synuclein deposits: a biomarker for idiopathic Parkinson disease. *Neurology* 82:1362–1369
- Donlon E, Lynch R, Murphy OC, Farrell M, Noel J, Keogan M, O'Connell M, Lynch T (2021) Braak's unfinished hypothesis: a clinicopathological case report of alpha-synuclein peripheral neuropathy preceding Parkinsonism by 20 years. *Mov Disord Clin Pract* 8:1129–1133
- Yang J, Wang H, Yuan Y, Fan S, Li L, Jiang C, Mao C, Shi C, Xu Y (2021) Peripheral synucleinopathy in Parkinson disease with LRRK2 G2385R variants. *Ann Clin Transl Neurol* 8:592–602
- Zhang H, Zhu L, Sun L, Zhi Y, Ding J, Yuan YS, Shen FF, Li X, Ji P, Wang Z, Niu Q, Zhang KZ (2019) Phosphorylated alpha-synuclein deposits in sural nerve deriving from Schwann cells: a biomarker for Parkinson's disease. *Parkinsonism Relat Disord* 60:57–63
- Donadio V, Incensi A, Rizzo G, Capellari S, Pantieri R, Stanzani Maserati M, Devigili G, Eleopra R, Defazio G, Montini F, Baruzzi A, Liguori R (2017) A new potential biomarker for dementia with Lewy bodies: Skin nerve alpha-synuclein deposits. *Neurology* 89:318–326
- Donadio V, Wang Z, Incensi A, Rizzo G, Fileccia E, Vacchiano V, Capellari S, Magnani M, Scaglione C, Stanzani Maserati M, Avoni P, Liguori R, Zou W (2021) In vivo diagnosis of synucleinopathies: a comparative study of skin biopsy and RT-QulC. *Neurology* 96:e2513–e2524
- Dubey D, Lennon VA, Gadoth A, Pittock SJ, Flanagan EP, Schmeling JE, McKeon A, Klein CJ (2018) Autoimmune

- CRMP5 neuropathy phenotype and outcome defined from 105 cases. *Neurology* 90:e103–e110
29. Pittock SJ, Lucchinetti CF, Lennon VA (2003) Anti-neuronal nuclear autoantibody type 2: paraneoplastic accompaniments. *Ann Neurol* 53:580–587
 30. Dalmau J, Graus F, Villarejo A, Posner JB, Blumenthal D, Thiesen B, Saiz A, Meneses P, Rosenfeld MR (2004) Clinical analysis of anti-Ma2-associated encephalitis. *Brain* 127:1831–1844
 31. Mathew RM, Vandenberghe R, Garcia-Merino A, Yamamoto T, Landolfi JC, Rosenfeld MR, Rossi JE, Thiessen B, Dropcho EJ, Dalmau J (2007) Orchiectomy for suspected microscopic tumor in patients with anti-Ma2-associated encephalitis. *Neurology* 68:900–905
 32. Gwathmey KG (2016) Sensory neuronopathies. *Muscle Nerve* 53:8–19
 33. Sharp L, Vernino S (2012) Paraneoplastic neuromuscular disorders. *Muscle Nerve* 46:841–850
 34. Irani SR, Pettingill P, Kleopa KA, Schiza N, Waters P, Mazia C, Zuliani L, Watanabe O, Lang B, Buckley C, Vincent A (2012) Morvan syndrome: clinical and serological observations in 29 cases. *Ann Neurol* 72:241–255
 35. Baizabal-Carvallo JF, Jankovic J (2018) Autoimmune and paraneoplastic movement disorders: an update. *J Neurol Sci* 385:175–184
 36. Miesbach W (2008) Neurologic symptoms as a feature of the antiphospholipid syndrome. *Semin Thromb Hemost* 34:286–289
 37. Baizabal-Carvallo JF, Bonnet C, Jankovic J (2013) Movement disorders in systemic lupus erythematosus and the antiphospholipid syndrome. *J Neural Transm* 120:1579–1589
 38. Kampylafka EI, Alexopoulos H, Kosmidis ML, Panagiotakos DB, Vlachoyiannopoulos PG, Dalakas MC, Moutsopoulos HM, Tzioufas AG (2013) Incidence and prevalence of major central nervous system involvement in systemic lupus erythematosus: a 3-year prospective study of 370 patients. *PLoS ONE* 8:e55843
 39. Cervera R, Asherson RA, Font J, Tikly M, Pallares L, Chamorro A, Ingelmo M (1997) Chorea in the antiphospholipid syndrome. Clinical, radiologic, and immunologic characteristics of 50 patients from our clinics and the recent literature. *Medicine (Baltimore)* 76:203–212
 40. Plowman EK, Okun MS (2011) Antiphospholipid syndrome and other lupus-related movement disorders. *Handb Clin Neurol* 100:237–245
 41. Riva N, Gentile F, Cerri F, Gallia F, Podini P, Dina G, Falzone YM, Fazio R, Lunetta C, Calvo A, Logroscino G, Lauria G, Corbo M, Iannaccone S, Chio A, Lazzarini A, Nobile-Orazio E, Filippi M, Quattrini A (2022) Phosphorylated TDP-43 aggregates in peripheral motor nerves of patients with amyotrophic lateral sclerosis. *Brain* 145:276–284
 42. Oomatia A, Fang H, Petri M, Birnbaum J (2014) Peripheral neuropathies in systemic lupus erythematosus: clinical features, disease associations, and immunologic characteristics evaluated over a twenty-five-year study period. *Arthritis Rheumatol* 66:1000–1009
 43. Lachhab L, Regragui W, Hamaz S, Ait Benhaddou EH, Benomar A, Yahyaoui M (2012) Parkinsonism as first manifestation of lupus. *Rev Neurol (Paris)* 168:990–991
 44. Chang CC, Lin TM, Chang YS, Chen WS, Sheu JJ, Chen YH, Chen JH (2018) Autoimmune rheumatic diseases and the risk of Parkinson disease: a nationwide population-based cohort study in Taiwan. *Ann Med* 50:83–90
 45. Wang JD, Huang CC, Hwang YH, Chiang JR, Lin JM, Chen JS (1989) Manganese induced parkinsonism: an outbreak due to an unrepaired ventilation control system in a ferromanganese smelter. *Br J Ind Med* 46:856–859
 46. Huang CC, Chu NS, Lu CS, Calne DB (1997) Cock gait in manganese intoxication. *Mov Disord* 12:807–808
 47. Huang CC, Chu NS, Lu CS, Wang JD, Tsai JL, Tzeng JL, Wolters EC, Calne DB (1989) Chronic manganese intoxication. *Arch Neurol* 46:1104–1106
 48. Arjona A, Mata M, Bonet M (1997) Diagnosis of chronic manganese intoxication by magnetic resonance imaging. *N Engl J Med* 336:964–965
 49. Huang CC, Lu CS, Chu NS, Hochberg F, Lilienfeld D, Olanow W, Calne DB (1993) Progression after chronic manganese exposure. *Neurology* 43:1479–1483
 50. Soldin OP, Aschner M (2007) Effects of manganese on thyroid hormone homeostasis: potential links. *Neurotoxicology* 28:951–956
 51. Chu CC, Huang CC, Ryu SJ, Wu TN (1998) Chronic inorganic mercury induced peripheral neuropathy. *Acta Neurol Scand* 98:461–465
 52. Jung HH, Danek A, Walker RH (2011) Neuroacanthocytosis syndromes. *Orphanet J Rare Dis* 6:68
 53. Bader B, Walker RH, Vogel M, Prosiegel M, McIntosh J, Danek A (2010) Tongue protrusion and feeding dystonia: a hallmark of chorea-acanthocytosis. *Mov Disord* 25:127–129
 54. Walker RH, Jung HH, Danek A (2011) Neuroacanthocytosis. *Handb Clin Neurol* 100:141–151
 55. Jung HH, Russo D, Redman C, Brandner S (2001) Kell and XK immunohistochemistry in McLeod myopathy. *Muscle Nerve* 24:1346–1351
 56. Danek A, Tison F, Rubio J, Oechsner M, Kalckreuth W, Monaco AP (2001) The chorea of McLeod syndrome. *Mov Disord* 16:882–889
 57. Manto MU (2005) The wide spectrum of spinocerebellar ataxias (SCAs). *Cerebellum* 4:2–6
 58. Park H, Kim HJ, Jeon BS (2015) Parkinsonism in spinocerebellar ataxia. *Biomed Res Int* 2015:125273
 59. Charles P, Camuzat A, Benammar N, Sella F, Destee A, Bonnet AM, Lesage S, Le Ber I, Stevanin G, Durr A, Brice A, French Parkinson's Disease Genetic Study G (2007) Are interrupted SCA2 CAG repeat expansions responsible for parkinsonism? *Neurology* 69:1970–1975
 60. Kim JY, Kim SY, Kim JM, Kim YK, Yoon KY, Kim JY, Lee BC, Kim JS, Paek SH, Park SS, Kim SE, Jeon BS (2009) Spinocerebellar ataxia type 17 mutation as a causative and susceptibility gene in parkinsonism. *Neurology* 72:1385–1389
 61. Lim SW, Zhao Y, Chua E, Law HY, Yuen Y, Pavanni R, Wong MC, Ng IS, Yoon CS, Puong KY, Lim SH, Tan EK (2006) Genetic analysis of SCA2, 3 and 17 in idiopathic Parkinson's disease. *Neurosci Lett* 403:11–14
 62. Bonnet C, Apartis E, Anheim M, Legrand AP, Baizabal-Carvallo JF, Bonnet AM, Durr A, Vidailhet M (2012) Tremor-spectrum in spinocerebellar ataxia type 3. *J Neurol* 259:2460–2470
 63. Lorincz MT (2018) Wilson disease and related copper disorders. *Handb Clin Neurol* 147:279–292
 64. Bandmann O, Weiss KH, Kaler SG (2015) Wilson's disease and other neurological copper disorders. *Lancet Neurol* 14:103–113
 65. Jung KH, Ahn TB, Jeon BS (2005) Wilson disease with an initial manifestation of polyneuropathy. *Arch Neurol* 62:1628–1631
 66. Sturniolo GC, Lazzarini D, Bartolo O, Berton M, Leonardi A, Fregona IA, Parrozzani R, Midena E (2015) Small fiber peripheral neuropathy in Wilson disease: an in vivo documentation by corneal confocal microscopy. *Invest Ophthalmol Vis Sci* 56:1390–1395
 67. Bansagi B, Lewis-Smith D, Pal E, Duff J, Griffin H, Pyle A, Muller JS, Rudas G, Aranyi Z, Lochmuller H, Chinnery PF, Horvath R (2016) Phenotypic convergence of Menkes and Wilson disease. *Neurol Genet* 2:e119
 68. Saifee TA, Schwingenschuh P, Reilly MM, Lunn MP, Katschnig P, Kassavetis P, Parees I, Manji H, Bhatia K, Rothwell JC,

- Edwards MJ (2013) Tremor in inflammatory neuropathies. *J Neurol Neurosurg Psychiatry* 84:1282–1287
69. Svahn J, Petiot P, Antoine JC, Vial C, Delmont E, Viala K, Steck AJ, Magot A, Cauquil C, Zarea A, Echaniz-Laguna A, Iancu F, Foglia R, Gueguen A, Magy L, Leger JM, Kuntzer T, Ferraud K, Lacour A, Camdessanche JP, Francophone anti MAGcG, (2018) Anti-MAG antibodies in 202 patients: clinicopathological and therapeutic features. *J Neurol Neurosurg Psychiatry* 89:499–505
 70. Nobile-Orazio E, Meucci N, Baldini L, Di Troia A, Scarlato G (2000) Long-term prognosis of neuropathy associated with anti-MAG IgM M-proteins and its relationship to immune therapies. *Brain* 123(Pt 4):710–717
 71. Devaux JJ, Miura Y, Fukami Y, Inoue T, Manso C, Belghazi M, Sekiguchi K, Kokubun N, Ichikawa H, Wong AH, Yuki N (2016) Neurofascin-155 IgG4 in chronic inflammatory demyelinating polyneuropathy. *Neurology* 86:800–807
 72. Shelly S, Klein CJ, Dyck PJB, Paul P, Mauermann ML, Berini SE, Howe B, Fryer JP, Basal E, Bakri HM, Laughlin RS, McKeeon A, Pittcock SJ, Mills J, Dubey D (2021) Neurofascin-155 Immunoglobulin Subtypes: Clinicopathologic Associations and Neurologic Outcomes. *Neurology* 97:e2392–e2403
 73. Liberatore G, De Lorenzo A, Giannotta C, Manganelli F, Filosto M, Cosentino G, Cocito D, Briani C, Cortese A, Fazio R, Lauria G, Clerici AM, Rosso T, Marfia GA, Antonini G, Cavaletti G, Carpo M, Doneddu PE, Spina E, Cotti Piccinelli S, Peci E, Querol L, Nobile-Orazio E (2022) Frequency and clinical correlates of anti-nerve antibodies in a large population of CIDP patients included in the Italian database. *Neurol Sci* 43(6):3939–3947
 74. Martin-Aguilar L, Lleixa C, Pascual-Goni E, Caballero-Avila M, Martinez-Martinez L, Diaz-Manera J, Rojas-Garcia R, Cortes-Vicente E, Turon-Sans J, de Luna N, Suarez-Calvet X, Gallardo E, Rajabally Y, Scotton S, Jacobs BC, Baars A, Cortese A, Vegetti E, Hofstberger R, Zimprich F, Roesler C, Nobile-Orazio E, Liberatore G, Hiew FL, Martinez-Pineiro A, Carvajal A, Pinar-Morales R, Uson-Martin M, Alberti O, Lopez-Perez MA, Marquez F, Pardo-Fernandez J, Munoz-Delgado L, Cabrera-Serrano M, Ortiz N, Bartolome M, Duman O, Bril V, Segura-Chavez D, Pitarokouli K, Steen C, Illa I, Querol L (2022) Clinical and Laboratory Features in Anti-NF155 Autoimmune Nodopathy. *Neurol Neuroimmunol Neuroinflamm* 9:e1098
 75. Dalakas MC, Engel WK (1981) Chronic relapsing (dysimmune) polyneuropathy: pathogenesis and treatment. *Ann Neurol* 9(Suppl):134–145
 76. Dalakas MC, Teravainen H, Engel WK (1984) Tremor as a feature of chronic relapsing and dysgammaglobulinemic polyneuropathies. Incidence and management *Arch Neurol* 41:711–714
 77. Busby M, Donaghy M (2003) Chronic dysimmune neuropathy. A subclassification based upon the clinical features of 102 patients. *J Neurol* 250:714–724
 78. Schwingenschuh P, Saifee TA, Katschnig-Winter P, Reilly MM, Lunn MP, Manji H, Aguirregomez M, Schmidt R, Bhatia KP, Rothwell JC, Edwards MJ (2013) Cerebellar learning distinguishes inflammatory neuropathy with and without tremor. *Neurology* 80:1867–1873
 79. Brooks D, Jenkins I, Bain P, Colebatch J, Thompson P, Findley L, Marsden C (1992) A comparison of the abnormal patterns of cerebral activation associated with neuropathic and essential tremor. *Neurology* 42:423
 80. Zis P, Rao DG, Hoggard N, Sarrigiannis PG, Hadjivassiliou M (2018) Anti-MAG associated cerebellar ataxia and response to rituximab. *J Neurol* 265:115–118
 81. Zech M, Brunet T, Skorvanek M, Blaschek A, Vill K, Hancker B, Huning I, Han V, Dosekova P, Gdovinova Z, Alhaddad B, Berutti R, Strom TM, Ruzicka E, Kamsteeg EJ, van der Smagt JJ, Wagner M, Jech R, Winkelmann J (2020) Recessive null-allele variants in MAG associated with spastic ataxia, nystagmus, neuropathy, and dystonia. *Parkinsonism Relat Disord* 77:70–75
 82. Monfrini E, Straniero L, Bonato S, Monzio Compagnoni G, Bordon A, Dilena R, Rinchetti P, Silipigni R, Ronchi D, Corti S, Comi GP, Bresolin N, Duga S, Di Fonzo A (2019) Neurofascin (NFASC) gene mutation causes autosomal recessive ataxia with demyelinating neuropathy. *Parkinsonism Relat Disord* 63:66–72
 83. Garg N, Heard RNS, Kiers L, Gerraty R, Yiannikas C (2017) Multifocal motor neuropathy presenting as pseudodystonia. *Mov Disord Clin Pract* 4:100–104
 84. Kumar N (2014) Chapter 60—Neurologic aspects of cobalamin (B12) deficiency. In: Biller J, Ferro JM (eds) *Handbook of clinical neurology*. Elsevier, pp 915–926
 85. Stabler SP (2013) Clinical practice. Vitamin B12 deficiency. *N Engl J Med* 368:149–160
 86. Reynolds E (2006) Vitamin B12, folic acid, and the nervous system. *Lancet Neurol* 5:949–960
 87. Bhoi SK, Jha M, Naik S, Palo GD (2019) Knuckle pigmentation, peripheral neuropathy, madness and abnormal movement: is it B12 deficiency? *Neurol Sci* 40:2399–2401
 88. de Souza A, Moloi MW (2014) Involuntary movements due to vitamin B12 deficiency. *Neurol Res* 36:1121–1128
 89. Yovera-Aldana M, Velasquez-Rimachi V, Huerta-Rosario A, More-Yupanqui MD, Osoreo-Flores M, Espinoza R, Gil-Olivares F, Quispe-Nolazco C, Quea-Velez F, Moran-Marinos C, Pinedo-Torres I, Alva-Diaz C, Pacheco-Barrios K (2021) Prevalence and incidence of diabetic peripheral neuropathy in Latin America and the Caribbean: a systematic review and meta-analysis. *PLoS ONE* 16:e0251642
 90. Cosentino C, Torres L, Nunez Y, Suarez R, Velez M, Flores M (2016) Hemichorea/hemiballism associated with hyperglycemia: report of 20 cases. *Tremor Other Hyperkinet Mov* 6:402
 91. Oh SH, Lee KY, Im JH, Lee MS (2002) Chorea associated with non-ketotic hyperglycemia and hyperintensity basal ganglia lesion on T1-weighted brain MRI study: a meta-analysis of 53 cases including four present cases. *J Neurol Sci* 200:57–62
 92. Jabbari B, Vaziri ND (2018) The nature, consequences, and management of neurological disorders in chronic kidney disease. *Hemodial Int* 22:150–160
 93. Park JW, Kim SU, Choi JY, Jung JM, Kwon DY, Park MH (2015) Reversible parkinsonism with lentiform fork sign as an initial and dominant manifestation of uremic encephalopathy. *J Neurol Sci* 357:343–344
 94. Jones MR, Urits I, Wolf J, Corrigan D, Colburn L, Peterson E, Williamson A, Viswanath O (2020) Drug-induced peripheral neuropathy: a narrative review. *Curr Clin Pharmacol* 15:38–48
 95. Morgan JC, Sethi KD (2005) Drug-induced tremors. *Lancet Neurol* 4:866–876
 96. Chuang C, Constantino A, Balmaceda C, Eidelberg D, Frucht SJ (2003) Chemotherapy-induced parkinsonism responsive to levodopa: an underrecognized entity. *Mov Disord* 18:328–331
 97. Cardoso FE, Jankovic J (1993) Hereditary motor-sensory neuropathy and movement disorders. *Muscle Nerve* 16:904–910
 98. Pareyson D, Piscosquito G, Moroni I, Salsano E, Zeviani M (2013) Peripheral neuropathy in mitochondrial disorders. *Lancet Neurol* 12:1011–1024
 99. Aerts MB, Weterman MA, Quadri M, Schelhaas HJ, Bloem BR, Esselink RA, Baas F, Bonifati V, van de Warrenburg BP (2016) A LRSAM1 mutation links Charcot-Marie-Tooth type 2 to Parkinson's disease. *Ann Clin Transl Neurol* 3:146–149
 100. Zimmermann M, Schuster S, Boesch S, Korenke GC, Mohr J, Reichbauer J, Kernstock C, Kotzot D, Spahlinger V, Schule-Freyer R, Schols L (2020) FIG4 mutations leading to parkinsonism and a phenotypical continuum between CMT4J and Yunis Varon syndrome. *Parkinsonism Relat Disord* 74:6–11

101. Posada IJ, Dominguez-Gonzalez C (2020) CMT4J, parkinsonism and a new FIG4 mutation. *Parkinsonism Relat Disord* 81:82–83
102. Raju S, Medarametla S, Boraiah N (2021) Dystonia and hereditary motor sensory neuropathy 6B due to SLC25A46 gene mutations. *Mov Disord Clin Pract* 8:480–482
103. Bitetto G, Malaguti MC, Ceravolo R, Monfrini E, Straniero L, Morini A, Di Giacomo R, Frosini D, Palermo G, Biella F, Ronchi D, Duga S, Taroni F, Corti S, Comi GP, Bresolin N, Giometto B, Di Fonzo A (2020) SLC25A46 mutations in patients with Parkinson's disease and optic atrophy. *Parkinsonism Relat Disord* 74:1–5
104. Shaibani A, Gooch C, Harati Y (1997) Moving toes and myoclonus associated with hereditary neuropathy with liability to pressure palsy (HNPP). *Muscle Nerve* 20:881–883
105. Macovei M, Alexianu M, Vasilescu C, Alexianu ME, Dan A, Burghelea B (1993) Chronic sensorimotor polyneuropathy associated with cerebello-extrapyramidal manifestations in a patient with tomaculous neuropathy. *Rom J Neurol Psychiatry* 31:279–281
106. Kulisevsky J, Marti-Fabregas J, Escartin A, Pradas J (1992) Brachial plexus palsy associated with spasmodic torticollis in a patient with tomaculous neuropathy. *Mov Disord* 7:186–187
107. Zhang J, Wang H, Liu W, Wang J, Zhang J, Chang X, Huang S, Pang X, Guo J, Wang Q, Zhang W (2021) A novel Q93H missense mutation in DCTN1 caused distal hereditary motor neuropathy type 7B and Perry syndrome from a Chinese family. *Neurol Sci* 42:3695–3705
108. Gallo JM, Leigh PN (2007) Chapter 8 Spinobulbar muscular atrophy (Kennedy's disease). *Handb Clin Neurol* 82:155–169
109. Finsterer J, Scorza FA (2019) Central nervous system abnormalities in spinal and bulbar muscular atrophy (Kennedy's disease). *Clin Neurol Neurosurg* 184:105426
110. Molnar MJ, Kovacs GG (2017) Mitochondrial diseases. *Handb Clin Neurol* 145:147–155
111. Ng YS, Bindoff LA, Gorman GS, Klopstock T, Kornblum C, Mancuso M, McFarland R, Sue CM, Suomalainen A, Taylor RW, Thorburn DR, Turnbull DM (2021) Mitochondrial disease in adults: recent advances and future promise. *Lancet Neurol* 20:573–584
112. Hudson G, Chinnery PF (2006) Mitochondrial DNA polymerase-gamma and human disease. *Hum Mol Genet* 15 Spec No 2:R244–252
113. Chinnery PF, Zeviani M (2008) 155th ENMC workshop: polymerase gamma and disorders of mitochondrial DNA synthesis, 21–23 September 2007, Naarden, The Netherlands. *Neuromuscul Disord* 18:259–267
114. Mancuso M, Orsucci D, Angelini C, Bertini E, Carelli V, Comi GP, Federico A, Minetti C, Moggio M, Mongini T, Tonin P, Toscano A, Bruno C, Ienco EC, Filosto M, Lamperti C, Diodato D, Moroni I, Musumeci O, Pegoraro E, Spinazzi M, Ahmed N, Sciacco M, Vercelli L, Ardisson A, Zeviani M, Siciliano G (2016) “Mitochondrial neuropathies”: a survey from the large cohort of the Italian Network. *Neuromuscul Disord* 26:272–276
115. Woodbridge P, Liang C, Davis RL, Vandebona H, Sue CM (2013) POLG mutations in Australian patients with mitochondrial disease. *Intern Med J* 43:150–156
116. Qiu J, Kumar KR, Watson E, Ahmad K, Sue CM, Hayes MW (2021) Dystonia responsive to dopamine: POLG mutations should be considered if sensory neuropathy is present. *J Mov Disord* 14:157–160
117. Orsucci D, Caldarazzo Ienco E, Mancuso M, Siciliano G (2011) POLG1-related and other “mitochondrial Parkinsonisms”: an overview. *J Mol Neurosci* 44:17–24
118. Martikainen MH, Ng YS, Gorman GS, Alston CL, Blakely EL, Schaefer AM, Chinnery PF, Burn DJ, Taylor RW, McFarland R, Turnbull DM (2016) Clinical, genetic, and radiological features of extrapyramidal movement disorders in mitochondrial disease. *JAMA Neurol* 73:668–674
119. Otero MG, Tiongson E, Diaz F, Haude K, Panzer K, Collier A, Kim J, Adams D, Tiftt CJ, Cui H, Millian Zamora F, Au MG, Graham JM Jr, Buckley DJ, Lewis R, Toro C, Bai R, Turner L, Mathews KD, Gahl W, Pierson TM (2019) Novel pathogenic COX20 variants causing dysarthria, ataxia, and sensory neuropathy. *Ann Clin Transl Neurol* 6:154–160
120. Lin CH, Tsai PI, Lin HY, Hattori N, Funayama M, Jeon B, Sato K, Abe K, Mukai Y, Takahashi Y, Li Y, Nishioka K, Yoshino H, Daida K, Chen ML, Cheng J, Huang CY, Tzeng SR, Wu YS, Lai HJ, Tsai HH, Yen RF, Lee NC, Lo WC, Hung YC, Chan CC, Ke YC, Chao CC, Hsieh ST, Farrer M, Wu RM (2020) Mitochondrial UQCRC1 mutations cause autosomal dominant parkinsonism with polyneuropathy. *Brain* 143:3352–3373
121. Lu JQ, Tarnopolsky MA (2021) Mitochondrial neuropathy and neurogenic features in mitochondrial myopathy. *Mitochondrion* 56:52–61
122. Cortese A, Simone R, Sullivan R, Vandrovцова J, Tariq H, Yau WY, Humphrey J, Jaunmuktane Z, Sivakumar P, Polke J, Ilyas M, Tribollet E, Tomaselli PJ, Devigili G, Callegari I, Versino M, Salpietro V, Efthymiou S, Kaski D, Wood NW, Andrade NS, Buglo E, Rebelo A, Rossor AM, Bronstein A, Fratta P, Marques WJ, Zuchner S, Reilly MM, Houlden H (2019) Biallelic expansion of an intronic repeat in RFC1 is a common cause of late-onset ataxia. *Nat Genet* 51:649–658
123. Boesch SM, Nance MA (2020) Intronic pentanucleotide expansion in the replication factor 1 gene (RFC1) is a major cause of adult-onset ataxia. *Neurol Genet* 6:e436
124. Cortese A, Tozza S, Yau WY, Rossi S, Beecroft SJ, Jaunmuktane Z, Dyer Z, Ravenscroft G, Lamont PJ, Mossman S, Chancellor A, Maisonobe T, Pereon Y, Cauquil C, Colnaghi S, Mallucci G, Curro R, Tomaselli PJ, Thomas-Black G, Sullivan R, Efthymiou S, Rossor AM, Laura M, Pipis M, Horga A, Polke J, Kaski D, Horvath R, Chinnery PF, Marques W, Tassorelli C, Devigili G, Leonardis L, Wood NW, Bronstein A, Giunti P, Zuchner S, Stojkovic T, Laing N, Roxburgh RH, Houlden H, Reilly MM (2020) Cerebellar ataxia, neuropathy, vestibular areflexia syndrome due to RFC1 repeat expansion. *Brain* 143:480–490
125. Cortese A, Reilly MM, Houlden H. RFC1 CANVAS/Spectrum Disorder. 2020 Nov 25. In: Adam MP, Ardinger HH, Pagon RA, et al., editors. *GeneReviews*® [Internet]. Seattle (WA): University of Washington, Seattle; 1993–2022. Available from: <https://www.ncbi.nlm.nih.gov/books/NBK564656/>
126. Curro R, Salvalaggio A, Tozza S, Gemelli C, Dominik N, Galassi Deforie V, Magrinelli F, Castellani F, Vegezzi E, Businaro P, Callegari I, Pichiecchio A, Cosentino G, Alfonsi E, Marchioni E, Colnaghi S, Gana S, Valente EM, Tassorelli C, Efthymiou S, Facchini S, Carr A, Laura M, Rossor AM, Manji H, Lunn MP, Pegoraro E, Santoro L, Grandis M, Bellone E, Beauchamp NJ, Hadjivassiliou M, Kaski D, Bronstein AM, Houlden H, Reilly MM, Mandich P, Schenone A, Manganelli F, Briani C, Cortese A (2021) RFC1 expansions are a common cause of idiopathic sensory neuropathy. *Brain* 144:1542–1550
127. Szmulewicz DJ, Roberts L, McLean CA, MacDougall HG, Halmagyi GM, Storey E (2016) Proposed diagnostic criteria for cerebellar ataxia with neuropathy and vestibular areflexia syndrome (CANVAS). *Neurol Clin Pract* 6:61–68
128. Traschütz A, Cortese A, Reich S, Dominik N, Faber J, Jacobi H, Hartmann AM, Rujescu D, Montaut S, Echaniz-Laguna A, Erer S, Schutz VC, Tarnutzer AA, Sturm M, Haack TB, Vaucamps-Diedhiou N, Puccio H, Schols L, Klockgether T, van de Warrenburg BP, Paucar M, Timmann D, Hilgers RD, Gazulla J, Strupp M, Moris G, Filla A, Houlden H, Anheim M, Infante J, Basak AN, Synofzik M, Group RFCS (2021) Natural history,

- phenotypic spectrum, and discriminative features of multisystemic RFC1 disease. *Neurology* 96:e1369–e1382
129. Kytovuori L, Sipilä J, Doi H, Hurme-Niiranen A, Siitonen A, Koshimizu E, Miyatake S, Matsumoto N, Tanaka F, Majamaa K (2022) Biallelic expansion in RFC1 as a rare cause of Parkinson's disease. *NPJ Parkinsons Dis* 8:6
 130. Robertson EE, Hall DA, McAsey AR, O'Keefe JA (2016) Fragile X-associated tremor/ataxia syndrome: phenotypic comparisons with other movement disorders. *Clin Neuropsychol* 30:849–900
 131. Apartis E, Blancher A, Meissner WG, Guyant-Marechal L, Maltete D, De Broucker T, Legrand AP, Bouzenada H, Thanh HT, Sallansonnet-Froment M, Wang A, Tison F, Roue-Jagot C, Sedel F, Charles P, Whalen S, Heron D, Thobois S, Poisson A, Lesca G, Ouvrard-Hernandez AM, Fraix V, Palfi S, Habert MO, Gaymard B, Dussaule JC, Pollak P, Vidailhet M, Durr A, Barbot JC, Gourlet V, Brice A, Anheim M (2012) FXTAS: new insights and the need for revised diagnostic criteria. *Neurology* 79:1898–1907
 132. Perlman SL (2011) Spinocerebellar degenerations. *Handb Clin Neurol* 100:113–140
 133. Renaud M, Tranchant C, Koenig M, Anheim M (2020) Autosomal recessive cerebellar ataxias with elevated alpha-fetoprotein: uncommon diseases, common biomarker. *Mov Disord* 35:2139–2149
 134. Lecocq C, Charles P, Azulay JP, Meissner W, Rai M, N'Guyen K, Pereon Y, Fabre N, Robin E, Courtois S, Guyant-Marechal L, Zagnoli F, Rudolf G, Renaud M, Sevin-Allouet M, Lesne F, Alaerts N, Goizet C, Calvas P, Eusebio A, Guissart C, Derkinderen P, Tison F, Brice A, Koenig M, Pandolfo M, Tranchant C, Durr A, Anheim M (2016) Delayed-onset Friedreich's ataxia revisited. *Mov Disord* 31:62–69
 135. Beaudin M, Manto M, Schmahmann JD, Pandolfo M, Dupre N (2022) Recessive cerebellar and afferent ataxias: clinical challenges and future directions. *Nat Rev Neurol*
 136. Garcia Ruiz PJ, Mayo D, Hernandez J, Cantarero S, Ayuso C (2002) Movement disorders in hereditary ataxias. *J Neurol Sci* 202:59–64
 137. Anheim M, Monga B, Fleury M, Charles P, Barbot C, Salih M, Delaunoy JP, Fritsch M, Arning L, Synofzik M, Schols L, Sequeiros J, Goizet C, Marelli C, Le Ber I, Koht J, Gazulla J, De Bleecker J, Mukhtar M, Drouot N, Ali-Pacha L, Benhassine T, Chbicheb M, M'Zahem A, Hamri A, Chabrol B, Pouget J, Murphy R, Watanabe M, Coutinho P, Tazir M, Durr A, Brice A, Tranchant C, Koenig M (2009) Ataxia with oculomotor apraxia type 2: clinical, biological and genotype/phenotype correlation study of a cohort of 90 patients. *Brain* 132:2688–2698
 138. Pedroso JL, Vale TC, da Costa SCG, Santos M, Alonso I, Barsottini OGP (2020) Complex movement disorders in ataxia with oculomotor apraxia type 1: beyond the cerebellar syndrome. *Tremor Other Hyperkinet Mov (N Y)* 10:39
 139. Shimazaki H, Kobayashi J, Sugaya R, Nakano I, Fujimoto S (2020) Late-onset autosomal recessive cerebellar ataxia and neuropathy with a novel splicing mutation in the ATM gene. *J Integr Neurosci* 19:125–129
 140. Fink JK (2013) Hereditary spastic paraplegia: clinico-pathologic features and emerging molecular mechanisms. *Acta Neuropathol* 126:307–328
 141. Pensato V, Castellotti B, Gellera C, Pareyson D, Ciano C, Nanetti L, Salsano E, Piscosquito G, Sarto E, Eoli M, Moroni I, Soliveri P, Lamperti E, Chiapparini L, Di Bella D, Taroni F, Mariotti C (2014) Overlapping phenotypes in complex spastic paraplegias SPG11, SPG15, SPG35 and SPG48. *Brain* 137:1907–1920
 142. Hirst J, Madeo M, Smets K, Edgar JR, Schols L, Li J, Yarrow A, Deconinck T, Baets J, Van Aken E, De Bleecker J, Datiles MB 3rd, Roda RH, Liepert J, Zuchner S, Mariotti C, De Jonghe P, Blackstone C, Kruer MC (2016) Complicated spastic paraplegia in patients with AP5Z1 mutations (SPG48). *Neurol Genet* 2:e98
 143. Roubertie A, Charif M, Meyer P, Manes G, Meunier I, Taieb G, Junta Morales R, Guichet A, Delettre C, Sarzi E, Leboucq N, Rivier F, Lenaers G (2019) Hereditary spastic paraplegia and prominent sensorial involvement: think MAG mutations! *Ann Clin Transl Neurol* 6:1572–1577
 144. Guidubaldi A, Piano C, Santorelli FM, Silvestri G, Petracca M, Tessa A, Bentivoglio AR (2011) Novel mutations in SPG11 cause hereditary spastic paraplegia associated with early-onset levodopa-responsive Parkinsonism. *Mov Disord* 26:553–556
 145. De la Casa-Fages B, Fernandez-Eulate G, Gamez J, Barahona-Hernando R, Moris G, Garcia-Barcina M, Infante J, Zulaica M, Fernandez-Pelayo U, Munoz-Oreja M, Urtasun M, Olassoaga A, Zelaya V, Jerico I, Saez-Villaverde R, Catalina I, Sola E, Martinez-Saez E, Pujol A, Ruiz M, Schluter A, Spinazzola A, Munoz-Blanco JL, Grandas F, Holt I, Alvarez V, Lopez de Munain A (2019) Parkinsonism and spastic paraplegia type 7: expanding the spectrum of mitochondrial Parkinsonism. *Mov Disord* 34:1547–1561
 146. Anheim M, Lagier-Tourenne C, Stevanin G, Fleury M, Durr A, Namer IJ, Denora P, Brice A, Mandel JL, Koenig M, Tranchant C (2009) SPG11 spastic paraplegia. A new cause of juvenile parkinsonism. *J Neurol* 256:104–108
 147. Goizet C, Boukhris A, Mundwiller E, Tallaksen C, Forlani S, Toutain A, Carriere N, Paquis V, Depienne C, Durr A, Stevanin G, Brice A (2009) Complicated forms of autosomal dominant hereditary spastic paraplegia are frequent in SPG10. *Hum Mutat* 30:E376–385
 148. Nemani T, Steel D, Kaliakatsos M, DeVile C, Ververi A, Scott R, Getov S, Sudhakar S, Male A, Mankad K, Genomics England Research C, Muntoni F, Reilly MM, Kurian MA, Carr L, Munton P (2020) KIF1A-related disorders in children: A wide spectrum of central and peripheral nervous system involvement. *J Peripher Nerv Syst* 25:117–124